

# Improvement of Naturally Aged Skin With Vitamin A (Retinol)

Reza Kafi, MD; Heh Shin R. Kwak, MD; Wendy E. Schumacher, BS; Soyun Cho, MD, PhD; Valerie N. Hanft, MD; Ted A. Hamilton, MS; Anya L. King, MS; Jacqueline D. Neal, BSE; James Varani, PhD; Gary J. Fisher, PhD; John J. Voorhees, MD, FRCP; Sewon Kang, MD

**Objective:** To evaluate the effectiveness of topical retinol (vitamin A) in improving the clinical signs of naturally aged skin.

**Design:** Randomized, double-blind, vehicle-controlled, left and right arm comparison study.

**Setting:** Academic referral center.

**Patients:** The study population comprised 36 elderly subjects (mean age, 87 years), residing in 2 senior citizen facilities.

**Intervention:** Topical 0.4% retinol lotion or its vehicle was applied at each visit by study personnel to either the right or the left arm, up to 3 times a week for 24 weeks.

**Main Outcome Measures:** Clinical assessment using a semiquantitative scale (0, none; 9, most severe) and biochemical measurements from skin biopsy specimens obtained from treated areas.

**Results:** After 24 weeks, an intent-to-treat analysis using the last-observation-carried-forward method revealed that

there were significant differences between retinol-treated and vehicle-treated skin for changes in fine wrinkling scores ( $-1.64$  [95% CI,  $-2.06$  to  $-1.22$ ] vs  $-0.08$  [95% CI,  $-0.17$  to  $0.01$ ];  $P < .001$ ). As measured in a subgroup, retinol treatment significantly increased glycosaminoglycan expression ( $P = .02$  [ $n = 6$ ]) and procollagen I immunostaining ( $P = .049$  [ $n = 4$ ]) compared with vehicle.

**Conclusions:** Topical retinol improves fine wrinkles associated with natural aging. Significant induction of glycosaminoglycan, which is known to retain substantial water, and increased collagen production are most likely responsible for wrinkle effacement. With greater skin matrix synthesis, retinol-treated aged skin is more likely to withstand skin injury and ulcer formation along with improved appearance.

**Trial Registration:** clinicaltrials.gov Identifier: NCT00272610

*Arch Dermatol.* 2007;143:606-612

**W**RINKLES AND BROWN spots that represent aged features are accentuated in the habitually sun-exposed face and the back of the hands. In this premature skin aging (ie, photoaging), matrix degradation triggered by solar radiation is critical in causing the wrinkled phenotype,<sup>1,2</sup> and topical use of retinoids can offer clinical improvement.<sup>3,4</sup> Human skin not exposed to the

precipitated by inspecting the upper inner arm. Clinically evident atrophy of aged skin correlates histologically with thinner epidermis and dermis, with reduced numbers of keratinocytes and fibroblasts, respectively.<sup>7,8</sup> Reduced dermal thickness is a natural consequence of documented reduction in procollagen synthesis and constitutively elevated matrix metalloproteinases in naturally aged human skin.<sup>7</sup> In addition to these quantitative changes, there is a qualitative fragmentation of dermal collagen fibers.<sup>9</sup> These senescent changes partly explain the notably poor wound healing and propensity for chronic skin ulcerations seen in the elderly population. Such fragile skin is becoming a major public health issue as the population grows older. Safe and effective therapies to reverse the atrophy of natural skin aging do not exist currently.

**Author Affiliations:** Department of Dermatology, University of Michigan Medical School, Ann Arbor. Drs Kafi and Kwak are now with the Department of Dermatology, Stanford Medical School, Palo Alto, Calif, and Dr Cho is now with the Department of Dermatology, Seoul National University, Seoul, South Korea.

**CME course available at**  
[www.archdermatol.com](http://www.archdermatol.com)

sun also ages but less dramatically. In intrinsic, natural, or chronologic aging, skin loses its youthful appearance by becoming thinner, laxer, and more finely wrinkled.<sup>5,6</sup> These changes are readily ap-

This reflects our limited understanding of the natural skin aging process, as well as significant logistical challenges in conducting clinical studies in the geriatric population.

Among the clinical features of photoaging, wrinkles have been a focus of extensive studies over the past decade. Compared with sun-protected skin, such as the buttock, photoaged skin has less procollagen formation.<sup>10</sup> Well-established treatments for photoaging, such as carbon dioxide laser resurfacing<sup>11</sup> or topical retinoic acid,<sup>12,13</sup> stimulate procollagen synthesis and increase the mature collagen band in the high dermis (papillary dermis).<sup>14</sup> This increase in dermal collagen is associated with wrinkle effacement. Because accelerated skin aging due to excessive sun exposure has marked collagen deficiency and effective treatments for photoaging promote procollagen synthesis, we hypothesized that similar therapies might also improve the collagen deficiency found in intrinsic aging. For intrinsically aged skin, however, use of ablative lasers such as carbon dioxide is not feasible because it induces significant wounding that takes several weeks to heal. Topical retinoic acid and tazarotene, both approved for the treatment of photoaging, are not suitable for use in geriatric populations either because they consistently induce skin irritation at application sites.<sup>4,12,15</sup>

All-*trans*-retinol is a precursor to retinoic acid. When applied to human skin, it penetrates and is sequentially oxidized to retinoic acid, causing retinoic acid–like effects.<sup>16</sup> However, compared with retinoic acid, the ability of retinol to induce skin irritation is notably less, at least according to a 4-day patch test (an occlusive treatment).<sup>16,17</sup> Thus, retinol has the potential to deliver retinoic acid–like effects to human skin with improved tolerability. We report herein a geriatric clinical study (patients 80 years or older only) assessing the effectiveness of topical retinol in effacing fine wrinkling as a clinical end point for reversal of skin atrophy. This clinical observation is complemented by molecular measurements of procollagen and glycosaminoglycan (GAG).

## METHODS

### SUBJECTS

The protocol was approved by the University of Michigan Medical School institutional review board, and written informed consent was obtained from all subjects prior to enrollment. Eligible patients were 80 years or older, in relatively good health, and without active skin diseases involving the upper extremities. Forty-four subjects were screened for the study from March 2001 until December 2002. The last visit by a subject occurred in August 2002. A total of 36 subjects with a minimum age of 80 years from 2 senior citizen centers were enrolled in the study, and 23 subjects completed the entire study. The mean age was 87 years (range, 80–96 years), and the male-female ratio was 1:2.5. Exclusion criteria included topical corticosteroid or other topical drug use 2 weeks prior to study entry and hormone therapy for women 6 months prior to the study.

### TREATMENT

Treatment areas consisted of upper inner (sun-protected) portions of the arms bilaterally (0.4% retinol [vitamin A] lotion

was applied to one arm and its vehicle lotion was applied to the contralateral arm). Assignment of treatment was made through a computer-generated randomization code. Approximately 2 mL each of retinol and vehicle lotion were drawn via syringe and applied to the arm at each treatment session. These unoccluded topical retinol applications were performed up to 3 times per week (Monday, Wednesday, and Friday) for 24 weeks. The treated areas were not subsequently covered with clothing. Unblinded study personnel not involved in the evaluation of study subjects traveled to the 2 residential sites 3 times a week for 24 weeks to administer treatments in mid-afternoons. For subjects who experienced skin irritation or excessive dryness, treatments were discontinued for 1 or more treatment sessions until symptoms decreased. Subjects with unresolved irritation after 2 weeks without treatment were terminated from the study.

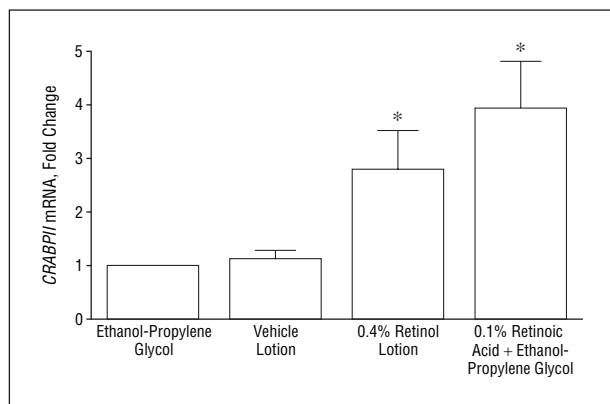
## RETINOL FORMULATION AND BIOACTIVITY

Retinol was formulated in the laboratory of 1 of the investigators (G.J.F.) by combining a 41% retinol solution in 55% polysorbate 20 in sufficient proportions with fragrance-free Norwegian Formula Neutrogena Body Moisturizer (Ortho-Neutrogena Co, Los Angeles, Calif) to yield a 0.4% retinol lotion. The vehicle was similarly prepared with 55% polysorbate 20 solution in Norwegian Formula Neutrogena Body Moisturizer. There were no discernable differences in color, odor, or consistency between the active lotion with retinol and the placebo lotion control. A stability study in our laboratory using high-performance liquid chromatography demonstrated that more than 90% of 0.4% retinol remained in the moisturizer 3 months after preparation. Therefore, 0.4% retinol lotion and vehicle were formulated every 2 months to ensure that adequate amounts of the active ingredient were present throughout the study. Both 0.4% retinol lotion and its vehicle were placed in dark glass containers covered with foil to eliminate transmission of UV radiation and stored at 4°C.

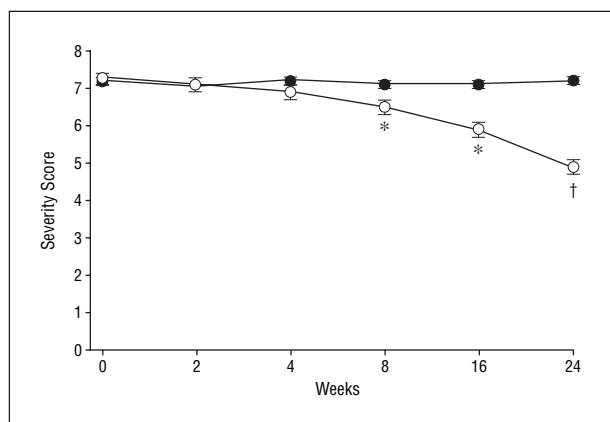
A separate bioactivity study using this 0.4% retinol formulation was also conducted on 5 healthy nongeriatric volunteers. This protocol was also approved by our institutional review board, and written informed consent was obtained from the subjects prior to enrollment. The *CRABP2* gene contains a retinoic acid–responsive element.<sup>18</sup> Its messenger RNA (mRNA) is induced by topical application of retinoids dose-dependently, thus serving as a reliable reporter of retinoid action.<sup>16,19</sup> Retinol lotion, its vehicle, 0.1% retinoic acid in ethanol-propylene glycol (positive control), and ethanol-propylene glycol (negative control) were applied on buttock skin, and a biopsy from each treatment site was obtained after 24 hours. *CRABP2* mRNA levels were measured with quantitative real-time reverse transcriptase–polymerase chain reaction (RT-PCR), as previously described.<sup>20</sup>

## CLINICAL EVALUATIONS

Evaluations were performed by 2 blinded dermatologists (V.N.H. and S.K.) at baseline and then at weeks 2, 4, 8, 16, and 24. Clinical evaluations of the upper inner arms were based on (1) tactile roughness, (2) fine wrinkling, and (3) overall severity. Each of these parameters was graded on a semiquantitative scale from 0 to 9 (0, none; 1–3, mild; 4–6, moderate; and 7–9, severe). Fine wrinkling was the primary outcome measure, while the overall severity was secondary. At each visit, subjects were also evaluated for signs of cutaneous irritation such as erythema, peeling, pruritus, burning and/or stinging, and dryness on a similar 9-point scale. Photographs of treatment areas were obtained at



**Figure 1.** Induction of *CRABP II* messenger RNA by 0.4% retinol preparation in human skin in vivo (n=5). Error bars indicate standard error. \* $P < .05$  vs control.



**Figure 2.** Topical retinol reduces the fine wrinkling in chronologically aged skin (n=23). Error bars indicate standard error. \* $P < .01$  vs vehicle. † $P < .001$  vs vehicle.

baseline and weeks 2, 4, 8, 16, and 24. For standardization, subjects were asked to stand erect and extend their arms 90° from the trunk laterally and gently place their hands (palm surface down) on a vertically placed pole.

### SKIN BIOPSY SPECIMENS

Four-millimeter punch biopsy specimens were taken from the upper inner arms on both retinol- and vehicle-treated arms at baseline and again at week 24. Biopsy specimens at week 24 were taken at least 2 cm away from the baseline biopsy sites to avoid inadvertent sampling of scar tissue. Biopsy specimens from each patient were assigned, through a randomization code, to one of several laboratory assays (immunohistologic and Western blot analyses, real-time RT-PCR, and transmission electron microscopy). Owing to a relatively small sample size in each category ( $\leq 6$  subjects), significant differences in measurements were not observed in most. Only the results of statistically significant effects are reported herein. Biopsy specimens for immunohistochemical analysis and GAG quantification were embedded in optimal cutting temperature medium and stored at  $-70^{\circ}\text{C}$  until use. For type I procollagen immunostaining, 7- $\mu\text{m}$  sections were cut and reacted with SP1.D8 monoclonal antibody (1.8  $\mu\text{g}/\text{mL}$ , from the University of Iowa Department of Biological Sciences, Iowa City), as previously described.<sup>10</sup> SP1 staining within the dermis was quantified using Image-Pro Plus software (Media Cybernetics, Silver Spring, Md).

Data were expressed as the percentage of dermal area stained. For GAG determination, eight 50- $\mu\text{m}$  sections were combined, washed with 50mM Tris (pH 8.0), digested with protease (500  $\mu\text{g}/\text{mL}$ ) (Sigma, St Louis, Mo), centrifuged for 15 minutes at 10 000g, and the supernatant assayed for GAG using a Blyscan Assay Kit (Biocolor Ltd, Belfast, Ireland) with the supplied GAG standard. Data were expressed as GAG (in micrograms) per volume (in microliters). *CRABP II* mRNA levels in skin samples were quantified by real-time RT-PCR, as previously described.<sup>21,22</sup> Forward and reverse primers and probe were 5'-CAAGACCTCGTGGACCAGAGA-3', 5'-ACCCTGGTG-CACACAACGT-3', and 6FAM-TCCGCCGTCATGGTCAG-GATCAGTTC, respectively.

### STATISTICAL ANALYSIS

Comparisons of clinical end points between vehicle- and retinol-treated skin were made with the paired *t* test. Subjects who withdrew prior to completion of the study had their last available global evaluation carried forward to week 24. Summary data are represented as mean  $\pm$  SE. All *P* values are 2 tailed. The data were analyzed using SAS analytic software (version 8.2, SAS Institute Inc, Cary, NC).

A sample size of 36 provides a power level of 0.80 in detecting a difference of 0.5 units on the overall global response scale between treated and untreated skin, with a type I error rate of 0.05 for a 2-tailed hypothesis, assuming a standard deviation of differences to be 1.0. This assumption was based on previous data from similar studies in photoaging.

## RESULTS

A total of 36 subjects were enrolled in the study. All were white with skin phototypes I or II. Eighteen were randomized to receive 0.4% retinol lotion on the right arm and 18 were randomized to receive lotion alone on the left arm. Among the 36 subjects, 23 completed the entire study and 13 withdrew prior to completion. Five subjects withdrew because of cutaneous irritation and/or pruritus (n=3), broken arm (n=1), and broken hip (n=1). Six subjects discontinued because of personal reasons, 1 withdrew owing to a protocol violation, and 1 subject died during the treatment period from a cause unrelated to the study.

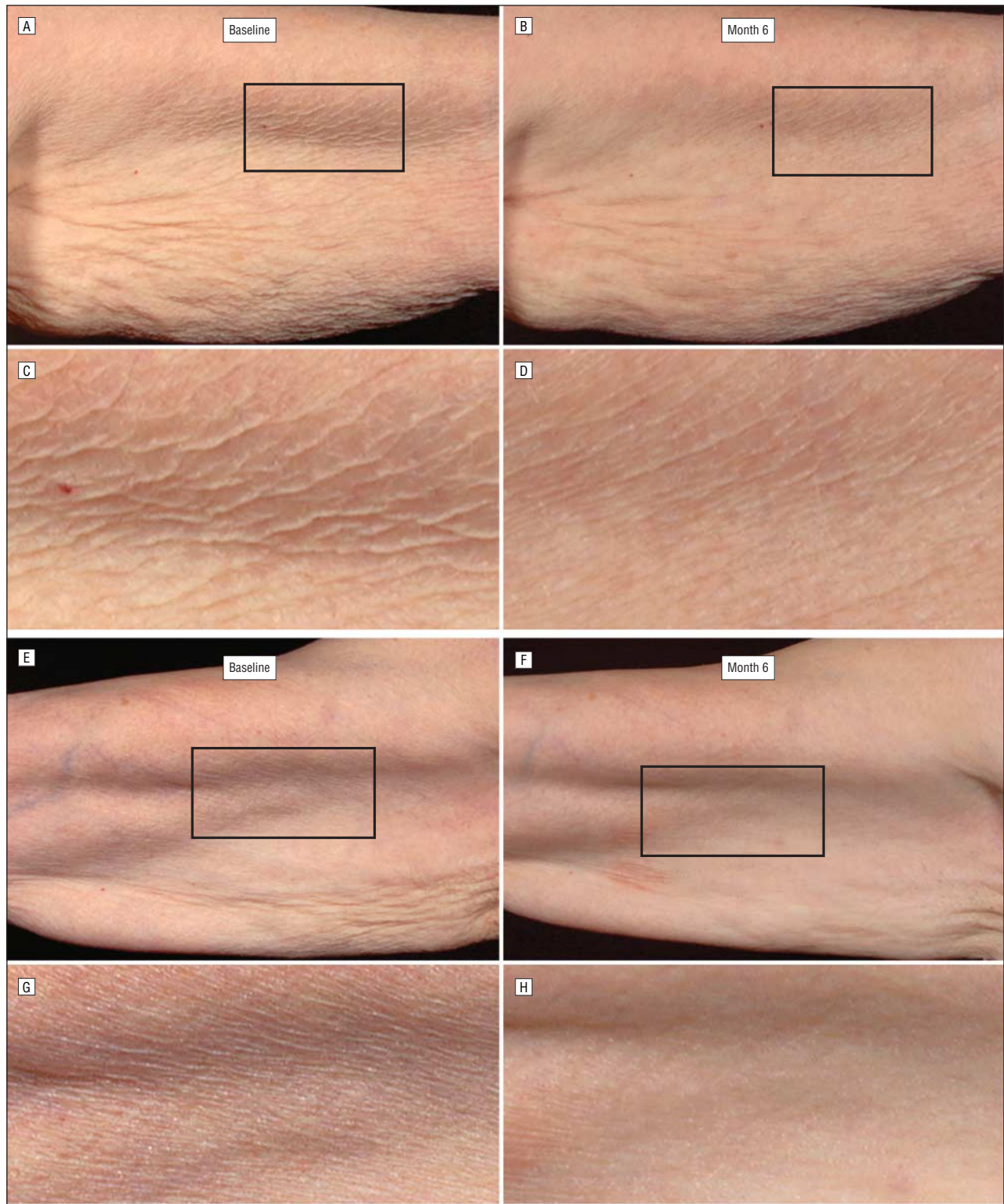
### RETINOL BIOACTIVITY RESULTS

Unoccluded application of 0.4% retinol lotion to normal human skin induced *CRABP II* mRNA 3-fold over its vehicle treatment ( $P < .05$ ; n=5). This magnitude of *CRABP II* mRNA induction was comparable to that seen with 0.1% retinoic acid, indicating retinol's ability to penetrate human skin and cause retinoid induced molecular changes (**Figure 1**).

### CLINICAL RESULTS

At baseline, clinical severity of the upper inner arms was similar between the left and right sides. For fine wrinkling, arms assigned to retinol treatment had a mean score of 7.25 (95% CI, 7.03 to 7.47) and those assigned to vehicle treatment, 7.22 (95% CI, 7.01 to 7.43). An analysis of all patients using the last-observation-carried-forward method revealed that retinol treatment





**Figure 3.** Clinical appearance of upper inner arms at baseline and end of study from 2 representative subjects (A and B; E and F). Magnifications (original magnification  $\times 3.5$ ) of the areas outlined with rectangles are also shown (C and D; G and H).

significantly reduced the fine wrinkling scores compared with vehicle treatment ( $-1.64$  [95% CI,  $-2.06$  to  $-1.22$ ] vs  $-0.08$  [95% CI,  $-0.17$  to  $0.01$ ];  $P < .001$  [N=36]). In an analysis restricted to patients completing the study ( $n=23$ ), the reduction in fine wrinkling was evident beginning at week 4 and continued through week 24

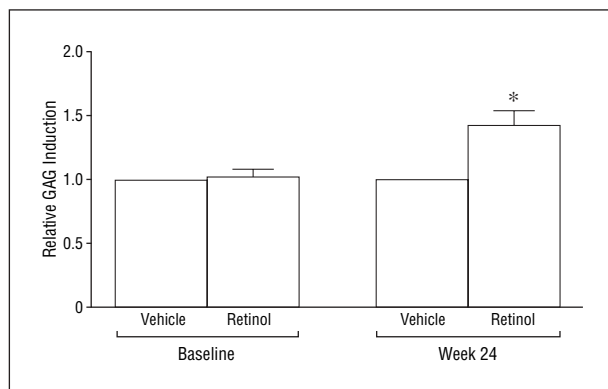
(**Figure 2**). Representative examples of clinical responses are seen in **Figure 3**.

Improvement in tactile roughness and overall severity in chronologically aged skin was also seen with retinol treatment. After 24 weeks, intent-to-treat analyses demonstrated significant differences between retinol-

**Table. Intent-to-Treat Analyses of 36 Patients Using the Last-Observation-Carried-Forward Method\***

Variable	Baseline Score	Score at Week 24	Change in Score at Week 24	P Value
Tactile roughness				
Retinol	4.64 (4.09 to 5.19)	4.11 (3.57 to 4.65)	-0.53 (-0.73 to -0.33)	<.001
Vehicle	4.64 (4.09 to 5.19)	4.64 (4.09 to 5.19)	0.00 (0.00 to 0.00)	
Fine wrinkling				
Retinol	7.25 (7.03 to 7.47)	5.61 (5.14 to 6.08)	-1.64 (-2.06 to -1.22)	<.001
Vehicle	7.22 (7.01 to 7.43)	7.14 (6.91 to 7.37)	-0.08 (-0.17 to 0.01)	
Overall severity				
Retinol	6.94 (6.75 to 7.14)	5.69 (5.24 to 6.14)	-1.25 (-1.63 to -0.87)	<.001
Vehicle	6.92 (6.73 to 7.10)	6.97 (6.77 to 7.17)	0.06 (-0.02 to 0.14)	

\*Data are given as mean score (95% confidence interval).



**Figure 4.** Topical retinol induces glycosaminoglycan (GAG) expression in chronologically aged skin (n=6). Values are ratios of levels in the retinol or vehicle at baseline and week 24. \*P=.04 vs baseline. Values in retinol-treated skin are expressed as fold change from vehicle-treated skin at baseline and again at week 24. After 24 weeks, the GAG levels in retinol-treated skin were 40% higher, on average, than in vehicle-treated skin (P=.02).

treated and vehicle-treated skin for changes in tactile roughness scores (-0.53 [95% CI, -0.73 to -0.33] vs 0.00 [95% CI, 0.00 to 0.00]; P<.001 [N=36]) and in the overall severity scores (-1.25 [95% CI, -1.63 to -0.87] vs 0.06 [95% CI, -0.02 to 0.14]; P<.001 [N=36]) (**Table**).

#### ADVERSE REACTIONS

Overall, topical retinol was well tolerated by the subjects. By week 24, most subjects reported some degree of cutaneous irritation on the retinol-treated arm, including erythema (n=18), peeling (n=16), pruritus (n=12), dryness (n=14), and burning and/or stinging (n=3). However, most adverse reactions to the retinol were rated as mild. In 3 subjects, cutaneous reactions and/or symptoms were severe enough to withdraw consent.

#### BIOCHEMICAL RESULTS

Compared with vehicle, retinol treatment induced a significant increase in GAG expression (P=.02 [n=6]) (**Figure 4**). In addition, a significant increase in procollagen I immunostaining from baseline to week 24 was observed in the retinol-treated arm compared with the vehicle-treated arm (P=.049 [n=4]) (**Figure 5**).

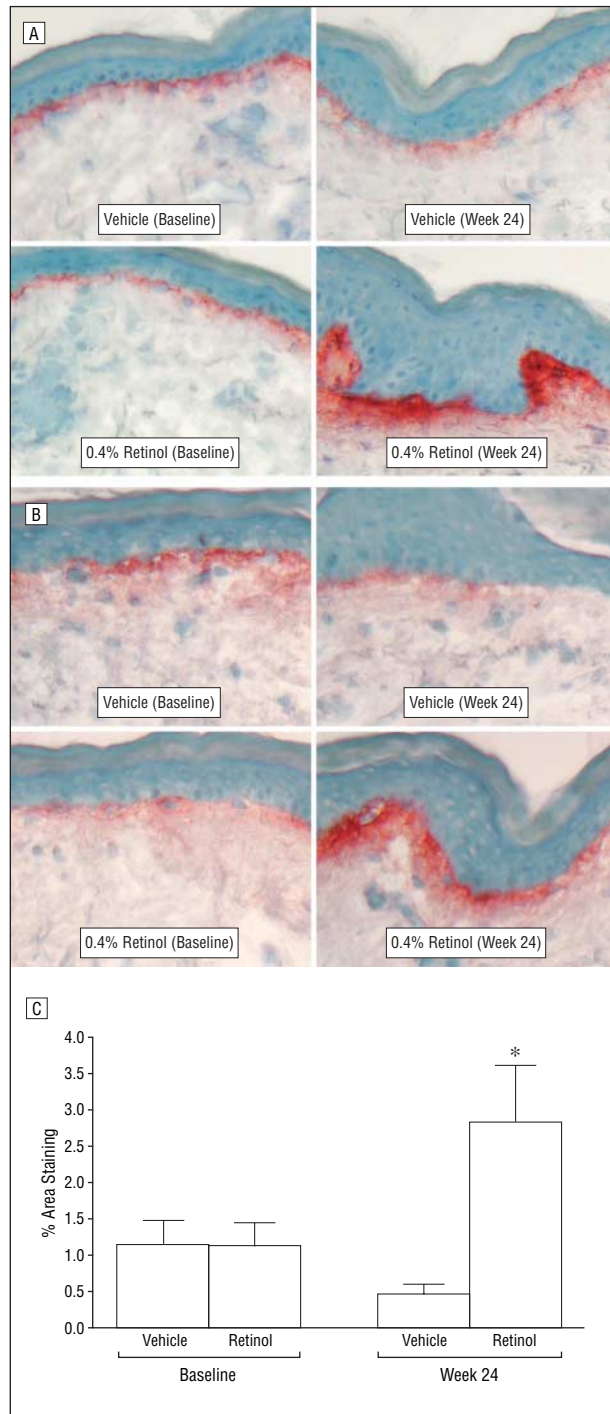
#### COMMENT

The age of the population is rapidly increasing. It is estimated that by the year 2040, greater than 30% of the US population will be older than 55 years, more than doubling its current level.<sup>23</sup> This increase in population age will be accompanied by greater demands on health care resources. Poor wound healing and propensity to form nonhealing ulcers (eg, decubitus ulcers), in addition to development of skin cancers, are considerable dermatologic issues in the elderly population. These clinical features of increased skin fragility are believed to result from cutaneous atrophy. Therefore, a safe and effective approach to increase the dermal matrix is desirable.

As human skin naturally ages, it becomes thin, lax, and finely wrinkled. Of these changes, fine wrinkles are most easily appreciated clinically, with severity correlating strongly with age.<sup>24</sup> We have demonstrated through this randomized controlled clinical trial that topical 0.4% retinol improves the clinical appearance of naturally aged human skin. This clinical improvement was accompanied by an increase in 2 matrix molecules, procollagen I, and GAG.

In our study, the fine wrinkles of intrinsic aging began to efface after 4 weeks of retinol use, with continued improvement throughout the study period of 24 weeks. This is a faster response in wrinkle effacement than that observed in photoaging. Typically, at least 2 to 3 months of topical retinoic acid therapy is needed before significant improvement in wrinkles or photoaging is noted.<sup>12,25,26</sup> The time-course differential in wrinkle effacement may reflect differences in the nature of wrinkles between photoaging and intrinsic aging and/or severity of the matrix deficiency to be overcome by retinoids.

Occurring within the first month of retinoic acid treatment, there is an increase in GAG (hyaluronic acid) in the epidermis of photoaged skin.<sup>3,27</sup> As a hygroscopic material, GAG possesses the capacity to bind water roughly 1000 times its own weight.<sup>28</sup> Well-established tactile smoothing of photoaged skin by topical retinoic acid is believed to be mediated by induced GAG retaining water in the superficial cutaneous compartment. In our study on intrinsic aging, measurement of GAG was performed prior to and after a 6-month treatment course with retinol. As a precursor to retinoic acid, retinol is expected to induce GAG early in the treatment course like reti-



**Figure 5.** Topical retinol induces type I procollagen protein in chronologically aged skin. Baseline and 24 weeks after retinol- or vehicle-treated skin was analyzed for type I procollagen by immunohistologic analysis (SP1 staining [reddish-brown color represents immunostaining], original magnification  $\times 20$ ). Panels A and B are from 2 representative subjects. Panel C summarizes quantitation (percentage of the dermis stained by SP1) of procollagen type I immunostaining ( $n=4$ ). Error bars indicate standard error. \* $P=.049$  for retinol vs control in the difference of percentage of area staining from baseline to week 24.

noic acid. Thus, the early effacement of fine wrinkles of natural aging brought on by topical retinol is most likely due in part to GAG.

Besides GAG, procollagen I was significantly induced by retinol treatment. The paucity of procollagen I

immunostaining at baseline indicates that there is minimal synthesis of collagen in intrinsically aged skin. Our study demonstrates that unoccluded treatment of retinol can stimulate procollagen synthesis in aged human skin. In photoaged human skin treated with topical retinoic acid for an extended length of time ( $>2$  years on average), we now have evidence that mature collagen matrix is deposited in the high dermis.<sup>14</sup> It is expected that a similar process will occur in intrinsically aged skin treated with retinol. Such skin may withstand skin breakdown and ulcer formation to a greater degree than untreated skin.

Of the 36 subjects enrolled in our study, 11 were assessed 12 weeks after the therapy was discontinued (week 36). Although the difference in fine wrinkle severity score had lessened between the retinol- and vehicle-treated sides, it remained statistically significant (data not shown). By week 48, 24 weeks after the discontinuation of retinol treatment, no significant differences remained between the 2 sides. In photoaging, a similar relapse in effaced wrinkling caused by retinoic acid treatment has been reported.<sup>29</sup>

Our retinol preparation was relatively well tolerated by the elderly subjects. Despite the known relatively low irritation potential of retinol,<sup>16</sup> we deliberately erred on the conservative side in administering topical treatments to maximize subject retention and tolerability in this fragile population. If there was any question or concern of excessive irritation, pruritus, or erythema, our trained treatment providers were instructed to withhold further topical application until the cutaneous reaction and symptoms abated or improved. These signs and symptoms (ie, retinoid dermatitis) have always been a source of potential bias in topical retinoid trials. Our gentle treatment approach minimized cutaneous reactions evident during patient evaluations and served to reduce but not totally eliminate the possibility of bias and blinding. Indeed, although up to 3 treatment sessions per week were planned, our patients received a mean of 1.6 applications weekly. We suspect that with a more aggressive treatment regimen, greater clinical effects and more robust biochemical changes would have been observed.

In summary, topical retinol is a promising and safe treatment to increase the dermal matrix of aged skin and improve clinical features associated with atrophic wrinkled skin. By increasing the dermal matrix of elderly skin, the substantial morbidity caused by poor wound healing and chronic ulcer formation may be reduced.

Accepted for Publication: October 19, 2006.

Correspondence: Sewon Kang, MD, University of Michigan Medical School, Department of Dermatology, 1910 Taubman Center, 1500 E Medical Center Dr, Ann Arbor, MI 48109 (swkang@med.umich.edu).

Author Contributions: Study concept and design: Kafi, Neal, Varani, Fisher, Voorhees, and Kang. Acquisition of data: Kafi, Kwak, Schumacher, Cho, Neal, Varani, Fisher, and Kang. Analysis and interpretation of data: Kafi, Kwak, Hamilton, King, Varani, Fisher, Voorhees, and Kang. Drafting of the manuscript: Kafi, Kwak, Schumacher, Neal, and Kang. Critical revision of the manuscript for important intellectual content: Kafi, Cho, Hamilton, King, Va-



rani, Fisher, Voorhees, and Kang. *Statistical analysis*: Hamilton and King. *Obtained funding*: Kafi, Voorhees, and Kang. *Administrative, technical, and material support*: Kafi, Kwak, Schumacher, Cho, King, Neal, Varani, Fisher, Voorhees, and Kang. *Study supervision*: Kafi, Voorhees, and Kang.

**Financial Disclosure**: Drs Fisher, Kang, Varani, and Voorhees are named inventors on an issued patent application concerning methods of treating skin aging. They will receive royalties under the University of Michigan's Intellectual Property Policy in the event that a commercial license is signed and a product is sold. This article describes research that was part of the basis of the approved application.

**Funding/Support**: This study was supported in part by grants from the Babcock Endowment for Dermatologic Research, the Merck-American Federation for Aging Research (Dr Kafi), Alpha Omega Alpha Student Research Fellowship (Dr Kafi), and the National Institutes of Health (K24, Dr Kang).

## REFERENCES

1. Fisher GJ, Datta S, Talwar HS, et al. Molecular basis of sun-induced premature skin aging and retinoid antagonism. *Nature*. 1996;379:335-339.
2. Fisher GJ, Wang ZQ, Datta SC, Varani J, Kang S, Voorhees JJ. Pathophysiology of premature skin aging induced by ultraviolet light. *N Engl J Med*. 1997;337:1419-1428.
3. Weiss JS, Ellis CN, Headington JT, et al. Topical tretinoin for photoaged skin: a double-blind vehicle-controlled study. *JAMA*. 1988;259:527-532.
4. Kang S, Leyden JJ, Lowe NJ, et al. Tazarotene cream for the treatment of facial photodamage: a multicenter, investigator-masked, randomized, vehicle-controlled, parallel comparison of tazarotene 0.01%, 0.025%, 0.05%, and 0.1% creams and tretinoin 0.05% emollient cream applied once-daily for 24 weeks. *Arch Dermatol*. 2001;137:1597-1604.
5. Fisher GJ, Kang S, Varani J, et al. Mechanisms of photoaging and chronological skin aging. *Arch Dermatol*. 2002;138:1462-1470.
6. Gilchrist BA. A review of skin ageing and its medical therapy. *Br J Dermatol*. 1996;135:867-875.
7. Varani J, Warner RL, Gharaee-Kermani M, et al. Vitamin A antagonizes decreased cell growth and elevated collagen-degrading matrix metalloproteinases and stimulates collagen accumulation in naturally aged human skin. *J Invest Dermatol*. 2000;114:480-486.
8. West MD. The cellular and molecular biology of skin aging. *Arch Dermatol*. 1994;130:87-95.
9. Pieraggi MT, Julian M, Bouissou H. Fibroblast changes in cutaneous aging. *Virchows Arch A Pathol Anat Histopathol*. 1984;402:275-287.
10. Griffiths CEM, Russman AN, Majmudar G, Singer RS, Hamilton TA, Voorhees JJ. Restoration of collagen formation in photodamaged human skin by tretinoin (retinoic acid). *N Engl J Med*. 1993;329:530-535.
11. Orringer JS, Kang S, Johnson TM, et al. Connective tissue remodeling induced by CO<sub>2</sub> laser resurfacing of photodamaged human skin. *Arch Dermatol*. 2004;140:1326-1332.
12. Griffiths CEM, Kang S, Ellis CN, et al. Two concentrations of topical tretinoin (retinoic acid) cause similar improvement of photoaging but different degrees of irritation: a double-blind, vehicle-controlled comparison of tretinoin 0.1% and 0.025% creams. *Arch Dermatol*. 1995;131:1037-1044.
13. Weinstein GD, Nigra TP, Pochi PE, et al. Topical tretinoin for treatment of photodamaged skin: a multicenter study. *Arch Dermatol*. 1991;127:659-665.
14. Cho S, Lowe L, Hamilton TA, Fisher GJ, Voorhees JJ, Kang S. Long-term treatment of photoaged human skin with topical retinoic acid improves epidermal cell atypia and thickens collagen band in the papillary dermis. *J Am Acad Dermatol*. 2005;53:769-774.
15. Kang S, Krueger G, Tanghetti E, et al. A multicenter, randomized, double-blind trial of tazarotene 0.1% cream in the treatment of photodamage. *J Am Acad Dermatol*. 2005;52:268-274.
16. Kang S, Duell EA, Fisher GJ, et al. Application of retinol to human skin in vivo induces epidermal hyperplasia and cellular retinoid binding proteins characteristic of retinoic acid but without measurable retinoic acid levels or irritation. *J Invest Dermatol*. 1995;105:549-556.
17. Kang S, Duell EA, Kim KJ, Voorhees JJ. Liarozole inhibits human epidermal retinoic acid 4-hydroxylase activity and differentially augments human skin responses to retinoic acid and retinol in vivo. *J Invest Dermatol*. 1996;107:183-187.
18. Astrom A, Pettersson U, Chambon P, Voorhees JJ. Retinoic acid induction of human cellular retinoic acid-binding protein-II gene transcription is mediated by retinoic acid receptor-retinoid X receptor heterodimers bound to one far upstream retinoic acid-responsive element with 5-base pair spacing. *J Biol Chem*. 1994;269:22334-22339.
19. Elder JT, Kaplan A, Cromie MA, Kang S, Voorhees JJ. Retinoid induction of CRABP-II mRNA in human dermal fibroblasts: use as a retinoid bioassay. *J Invest Dermatol*. 1996;106:517-521.
20. Fisher GJ, Datta S, Wang ZQ, et al. c-Jun-dependent inhibition of cutaneous procollagen transcription following ultraviolet irradiation is reversed by all-trans retinoic acid. *J Clin Invest*. 2000;106:663-670.
21. Quan T, He T, Kang S, Voorhees J, Fisher G. Solar ultraviolet irradiation reduces collagen in photoaged human skin by blocking transforming growth factor- $\beta$  type II receptor/Smad signaling. *Am J Pathol*. 2004;165:741-751.
22. Quan T, He T, Shao Y, et al. Elevated cysteine-rich 61 mediates aberrant collagen homeostasis in chronologically aged and photoaged human skin. *Am J Pathol*. 2006;169:482-490.
23. Smith ES, Fleischer AB Jr, Feldman SR. Demographics of aging and skin disease. *Clin Geriatr Med*. 2001;17:631-641.
24. Yu L, Rosi Y, Ofori A, King A, Voorhees JJ, Kang S. Intrinsic skin aging: validation of a photometric scale and risk factors that accelerate the process [abstract]. *J Invest Dermatol*. 2005;124:A54.
25. Kang S, Fisher GJ, Voorhees JJ. Photoaging and topical tretinoin: therapy, pathogenesis, and prevention. *Arch Dermatol*. 1997;133:1280-1284.
26. Kang S, Voorhees JJ. Photoaging therapy with topical tretinoin: an evidence-based analysis. *J Am Acad Dermatol*. 1998;39:S55-S61.
27. Fisher GJ, Tavakkol A, Griffiths CEM, et al. Differential modulation of transforming growth factor- $\beta$ , expression and mucin deposition by retinoic acid and sodium lauryl sulfate in human skin. *J Invest Dermatol*. 1992;98:102-108.
28. Silbert JE. Proteoglycans and glycosaminoglycans. In: Goldsmith LA, ed. *Biochemistry and Physiology of the Skin*. New York, NY: Oxford University; 1983:448-461.
29. Olsen EA, Katz HI, Levine N, et al. Sustained improvement in photodamaged skin with reduced tretinoin emollient cream treatment regimen: effect of once-weekly and three-times-weekly applications. *J Am Acad Dermatol*. 1997;37:227-230.